



ORIGINAL ARTICLE

**Intramedullary Interlocking Nailing Versus Minimally Invasive Percutaneous Plate Osteosynthesis for Extra-Articular Distal Third Tibial Fractures: A Prospective Comparative Study**

Balamurugan D,<sup>1,\*</sup> Bharath V<sup>2</sup> and Vignesh Karthick<sup>3</sup>

<sup>1</sup>Assistant Professor, Department of Orthopaedics, Kanniyakumari Medical Mission Reserach Centre, Muttam, Tamilnadu

<sup>2</sup>Associate Professor, Department of Orthopaedics, Vinayaka Misssions Medical College and Hospital, Karaikal, Tamilnadu

<sup>3</sup>Associate Professor, Department of Orthopaedics, Sri Lalithambigai Medical College and Hospital, Chennai, Tamil Nadu

Accepted: 16-June-2026 / Published Online: 2-July-2026

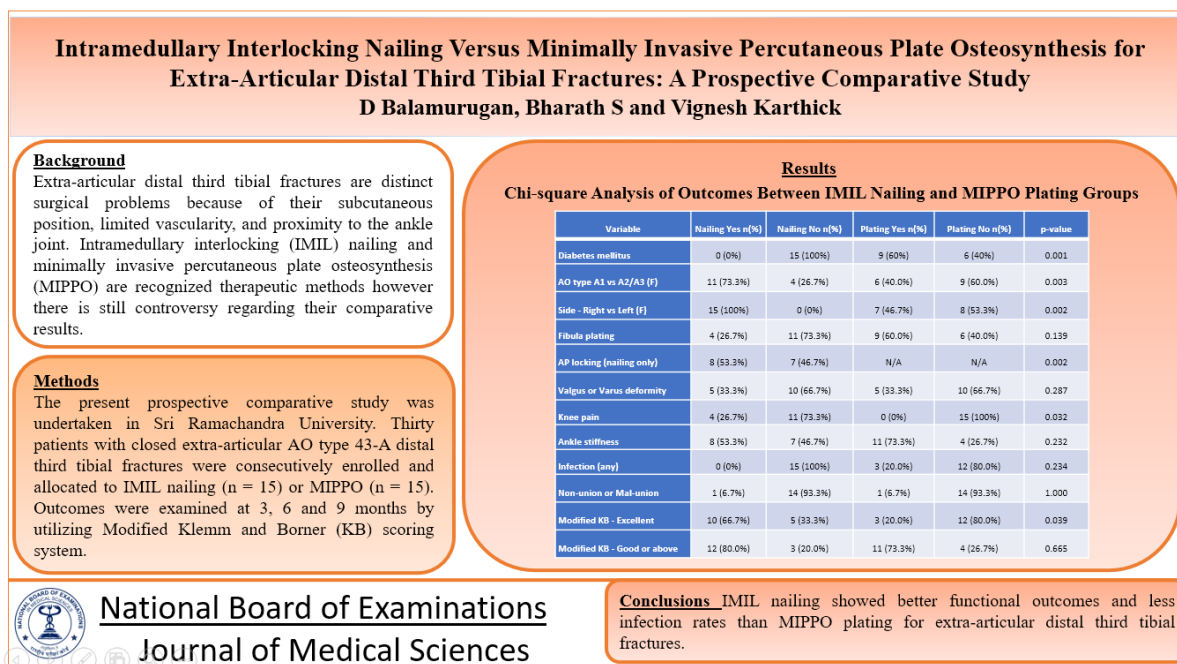
**Abstract**

**Background:** Extra-articular distal third tibial fractures (4 cm to 11 cm proximal to the tibial plafond) are distinct surgical problems because of their subcutaneous position, limited vascularity, and proximity to the ankle joint. Intramedullary interlocking (IMIL) nailing and minimally invasive percutaneous plate osteosynthesis (MIPPO) are recognized therapeutic methods however there is still controversy regarding their comparative results. **Objectives:** To compare clinical and radiological outcomes of IMIL nailing and MIPPO plating in extra-articular distal third tibial fractures. **Methods:** The present prospective comparative study was undertaken in Sri Ramachandra University. Thirty patients with closed extra-articular AO type 43-A distal third tibial fractures were consecutively enrolled and allocated to IMIL nailing (n = 15) or MIPPO (n = 15). Outcomes were examined at 3, 6 and 9 months by utilizing Modified Klemm and Borner (KB) scoring system. **Results:** Mean age was 29.87 years; 73.3% were men. Mean union time was substantially less in the nailing group (15.0 weeks vs 17.7 weeks). Nailing led to shorter post-operative immobilisation (6.27 vs 9.20 weeks; p=0.017). The Modified KB score showed excellent results in 66.7% in the nailing group and 20.0% in the plating group (p=0.039). Infection was not seen in the nailing group but occurred in three patients (20%) post plating. Incidence of mal-alignment was similar between groups (33.3% each; p=0.287). **Conclusions:** IMIL nailing showed better functional outcomes and less infection rates than MIPPO plating for extra-articular distal third tibial fractures. In the nailing procedure, correct guide-wire placement and AP locking are important in reducing mal-alignment. These results need to be confirmed in further randomized controlled trials with larger sample numbers.

**Keywords:** Distal tibia fracture, Intramedullary interlocking nailing, minimally invasive percutaneous plate osteosynthesis, MIPPO, AO classification, Functional outcome

\*Corresponding Author: Balamurugan D  
Email: balamuruganduraipandi@gmail.com

## Graphical Abstract



### Introduction

Extra-articular fractures of the distal portion of the tibia constitute over 10% of all tibial fractures and nevertheless pose a significant treatment challenge [1]. Anatomically adverse region: the bone is subcutaneous, the muscle envelope is sparse and the vascularity is intrinsically limited with respect to the diaphysis [2]. These factors predispose to wound problems, infection, delayed and non-union [3]. These fractures occur just proximal to the ankle joint and are therefore markedly different in etiology, displacement and prognosis from pilon injuries [4]. Historically the gold standard was open reduction and internal fixation (ORIF). However, infection (8.3-23%) and non-union (8.3-35%) rates led to the use of less invasive methods [5,6]. MIPPO was introduced as a biologically advantageous option by retaining the periosteal vascularity and fracture haematoma [7,8], but had the inherent risk of mal-union due

to indirect reduction and interposition of soft tissue between fracture segments. IMIL nailing has been established for diaphyseal tibial fractures for a long time, but has been extended to the distal metaphysis with some hesitancy due to concerns over the hourglass form of the distal canal, potential nail failure and the risk of propagating fracture lines into the ankle [9–11]. These restrictions have been mainly resolved by modifications such as antero-posterior (AP) locking screws and Poller blocking screws [12].

There is a large amount of research for both strategies, but there are few direct comparisons due to small sample numbers and insufficient randomisation. The present study was designed for the prospective comparison of clinical and radiological result of IMIL nailing and MIPPO plating in closed extra articular AO 43-A distal third tibial fractures.

## **Materials and Methods**

### ***Study design and setting***

The present prospective comparative study was undertaken in the Department of Orthopaedics, Sri Ramachandra Medical College and Research Institute, Chennai. Ethical approval was taken from the Institutional Ethics Board of the Institute before the start of the study.

### ***Study Participants***

Patients with closed extra-articular AO type 43-A distal one-third tibial fractures 4–11 cm proximal to the tibial plafond were included. Exclusion criteria included compound (open) fractures, intra-articular fractures, pathological fractures and pediatric fractures. All thirty eligible participants presented during the study period were included consecutively and non-randomly assigned to IMIL nailing (n=15) or MIPPO plating (n=15) according to fracture morphology and surgeon's evaluation. Fractures with AO 43-A1 morphology were nailed preferentially and plating was used for comminuted A3 patterns.

### ***Surgical Procedure***

MIPPO was done through an anteromedial incision of 3–5 cm in the distal tibia with a separate proximal stab incision. A locking compression plate (LCP) of 3.5 mm or 4.5 mm was tunneled subcutaneously and secured with distal locking head screws and proximal cortical screws. IMIL nailing was conducted with the patient in the supine position and the knee flexed at 90°. A reamed cannulated tibial nail was placed by an infrapatellar route. Cases at risk of mal-alignment had AP locking. The concomitant fixation of

the fibula was undertaken at the discretion of the surgeon.

Postoperative regimen. All patients were given intravenous broad-spectrum antibiotics for 5 postoperative days. Mobilisation of knee and ankle started on first post surgical day. Full weight-bearing was permitted once clinical and radiographic signs of fracture healing were obtained. Clinical and radiological follow up was done at 12, 18, 24, 30 and 36 weeks.

### ***Outcome evaluation***

The key end point was the Modified Klemm and Borner (KB) score at final follow-up. The KB score categorizes patients as Excellent (15 to 19), Good (10 to 14), Fair (5 to 9) or Poor (<5) on the basis of range of motion, discomfort, muscle atrophy, limb alignment and time to union. Time to fracture healing, period of post-operative immobilisation, incidence of infection, mal-alignment and necessity for subsequent surgical treatments were the secondary outcomes.

### ***Statistics***

Data were entered in excel and analysed using SPSS. Categorical variables were expressed in frequency, percentage. Continuous variables were expressed as mean with SD. Independent samples t-test was used for comparison of continuous variables and Chi-square or Fisher's exact test for categorical variables. Statistical significance was defined as a p-value of less than 0.05.

## **Results**

### ***Demographics and baseline attributes***

It included 30 patients (men, 22; women, 8; mean age, 29.87 years; range, 24 to 77 years). There were 13 patients with AO type 43-A1 fracture, 6 with 43-A2 and

11 with 43-A3. Nine had pre-existing diabetes mellitus ( $p = 0.001$ ) and five had hypertension ( $p = 0.330$ ). Eleven were smokers and seven consumed alcohols. All patients receiving nailing had fractures on the right side, whereas the plating group showed an equal incidence of right sided and left sided fractures. AP locking was used in eight patients in the nailing group and dramatically reduced mal-alignment ( $p=0.002$ ).

### **Union and immobilization**

The mean time to union was 15.0 weeks (range, 6 to 52) in the nailing group and 17.7 weeks (range, 6 to 32) in the plating group. Union was earlier with nailing but this difference was not statistically significant ( $p=0.308$ ). Post-operative immobilisation was considerably less in the nailing group (6.27 vs 9.20 weeks,  $p=0.017$ ). One patient in the nailing group had a non-union. Two patients in the dynamised group had become unionised by nine months. The plating group had no nonunion, however one patient had malunion with severe valgus deformity needing corrective surgery.

### **Complications**

In nailing group no patient had wound infection. There were three infections in plating patients (superficial two, deep one). The deep infection resulted in plate exposure and was handled with medicated dressings. The implant was held until radiological union and was removed after one year. Deformity was valgus in three nailing and five plating patients and varus in two nailing patients and none with plating ( $p=0.287$ ). Four nailing patients (26.7%) had anterior knee pain and none in the plating group. Ankle stiffness was seen in 53.3% (nailing) and 73.3% (plating) of the patients. One patient in the nailing group had a 0.3 cm tibial shortening.

### **Functional result**

The modified KB score at nine months was considerably better in the nailing group ( $p=0.039$ ). Excellent: 10 patients (66.7%) versus 3 (20.0%) with plating; Good: 2 (13.3%) versus 8 (53.3%); Fair: 3 (20.0%) versus 3 (20.0%); Poor: 0 versus 1 (6.7%) (Tables 1 and 2).

Table 1. Distribution of Variables by Treatment Group (IMIL Nailing vs MIPPO Plating)

<b>Variable</b>	<b>IMIL Nailing (n=15)</b>	<b>MIPPO Plating (n=15)</b>	<b>Total (n=30)</b>
<b>Gender</b>			
Male	11 (73.3%)	11 (73.3%)	22 (73.3%)
Female	4 (26.7%)	4 (26.7%)	8 (26.7%)
<b>Pre-existing Illness</b>			

<b>Variable</b>	<b>IMIL Nailing (n=15)</b>	<b>MIPPO Plating (n=15)</b>	<b>Total (n=30)</b>
Diabetes mellitus	0 (0.0%)	9 (60.0%)	9 (30.0%)
Hypertension	2 (13.3%)	3 (20.0%)	5 (16.7%)
Smoking	6 (40.0%)	5 (33.3%)	11 (36.7%)
Alcohol use	3 (20.0%)	4 (26.7%)	7 (23.3%)
<b>AO Fracture Type</b>			
43-A1 (Simple)	11 (73.3%)	2 (13.3%)	13 (43.3%)
43-A2 (Wedge)	2 (13.3%)	4 (26.7%)	6 (20.0%)
43-A3 (Complex)	2 (13.3%)	9 (60.0%)	11 (36.7%)
<b>Side of Fracture</b>			
Right	15 (100.0%)	7 (46.7%)	22 (73.3%)
Left	0 (0.0%)	8 (53.3%)	8 (26.7%)
<b>Concomitant Fibula Plating</b>			
Yes	4 (26.7%)	9 (60.0%)	13 (43.3%)
No	11 (73.3%)	6 (40.0%)	17 (56.7%)
<b>AP Locking (Nailing group only)</b>			
Yes	8 (53.3%)	N/A	N/A
No	7 (46.7%)	N/A	N/A

<b>Variable</b>	<b>IMIL Nailing (n=15)</b>	<b>MIPPO Plating (n=15)</b>	<b>Total (n=30)</b>
<b>Post-operative Immobilisation</b>			
Mean (weeks)	6.27	9.20	--
Range (weeks)	6 - 10	6 - 20	--
<b>Post-operative Deformity</b>			
Normal alignment	10 (66.7%)	10 (66.7%)	20 (66.7%)
Valgus deformity	3 (20.0%)	5 (33.3%)	8 (26.7%)
Varus deformity	2 (13.3%)	0 (0.0%)	2 (6.7%)
<b>Surgical Outcome - Modified KB Score</b>			
Excellent (15-19)	10 (66.7%)	3 (20.0%)	13 (43.3%)
Good (10-14)	2 (13.3%)	8 (53.3%)	10 (33.3%)
Fair (5-9)	3 (20.0%)	3 (20.0%)	6 (20.0%)
Poor (< 5)	0 (0.0%)	1 (6.7%)	1 (3.3%)
<b>Mean union time</b>	15.0 weeks	17.7 weeks	

Table 2. Chi-square Analysis of Categorical Outcomes Between IMIL Nailing and MIPPO Plating Groups

Variable	Nailing Yes n (%)	Nailing No n (%)	Plating Yes n (%)	Plating No n (%)	p-value
Diabetes mellitus	0 (0%)	15 (100%)	9 (60%)	6 (40%)	<b>0.001</b>
AO type A1 vs A2/A3 (F)	11 (73.3%)	4 (26.7%)	6 (40.0%)	9 (60.0%)	<b>0.003</b>
Side - Right vs Left (F)	15 (100%)	0 (0%)	7 (46.7%)	8 (53.3%)	<b>0.002</b>
Fibula plating	4 (26.7%)	11 (73.3%)	9 (60.0%)	6 (40.0%)	0.139
AP locking (nailing only)	8 (53.3%)	7 (46.7%)	N/A	N/A	<b>0.002</b>
Valgus or Varus deformity	5 (33.3%)	10 (66.7%)	5 (33.3%)	10 (66.7%)	0.287
Knee pain	4 (26.7%)	11 (73.3%)	0 (0%)	15 (100%)	<b>0.032</b>
Ankle stiffness	8 (53.3%)	7 (46.7%)	11 (73.3%)	4 (26.7%)	0.232
Infection (any)	0 (0%)	15 (100%)	3 (20.0%)	12 (80.0%)	0.234
Non-union or Mal- union	1 (6.7%)	14 (93.3%)	1 (6.7%)	14 (93.3%)	1.000
Modified KB - Excellent	10 (66.7%)	5 (33.3%)	3 (20.0%)	12 (80.0%)	<b>0.039</b>
Modified KB - Good or above	12 (80.0%)	3 (20.0%)	11 (73.3%)	4 (26.7%)	0.665

## Discussion

The treatment of extra-articular distal third tibial fractures remain a subject of ongoing debate. Both IMIL nailing and MIPPO plating are biological load sharing constructions that minimize further harm of the already degraded soft tissue envelope, but each technique has its own technical demands and complication profiles.

The present study showed that IMIL nailing achieved union approximately 2.7 weeks earlier than MIPPO plating with a considerably lesser length of immobilisation ( $p=0.017$ ) resulting in early functional rehabilitation. These results are in keeping with the findings of Im and Tae [13] who found union at 18 and 20 weeks respectively in a randomised study and Vallier et al. [14] who found union at 22.6 and 27.8 weeks. It is interesting to note that there were no infections in the nailing group, especially as open plating procedures have been documented in the literature with significant infection rates (up to 20%) [5]. Closed reduction and restricted contact with the nail are used to minimize bacterial colonization of the fracture hematoma.

The higher Modified KB scores in the nailing group (66.7% excellent vs 20.0%;  $p = 0.039$ ) represent the combined effect of quicker union, shorter immobilisation and retained periosteal circulation. Similar preponderance of excellent and good results with IMIL nailing in similar fracture patterns has also been observed by Singh et al. [15] and Mohamed et al. [16].

Mal-alignment was noted in five patients in each group (33.3%), a figure that lies between that reported by Vallier et al. [14] (23% nailing, 8.3% plating) and Natarajan et al. [17] (40% nailing, 13.3% plating). The use of AP locking screws in

the nailing group showed considerable reduction in mal-alignment ( $p=0.002$ ) validating the efficacy of this adjunct as stated by Krettek et al. with Poller blocking screws [12]. In the plating group mal-alignment was probably caused by indirect fracture reduction with soft tissue interposition between pieces as stated before [9].

Plating was associated with increased ankle stiffness (73.3% vs 53.3%), probably due to a longer time of immobilisation and more disturbance of periarticular soft tissue by the distal plate build. Anterior knee pain, a known consequence of the transpatellar nailing method, was seen in 26.7% of nailing patients and is in keeping with the literature of 10–40% [18].

Fibula fixation was performed concomitantly in 43.3% of the patients. Attal et al. [19] reported an 8-fold increase in delayed union with fibula fractures; however, the current study did not show a significant effect of fibula fixation on the union or functional outcome. This discovery needs additional study.

## Limitations

Certain limitations has to be considered while interpreting the findings. Baseline characteristics were not completely balanced between the treatment groups, with a higher prevalence of diabetes mellitus and a greater proportion of AO type 43-A3 comminuted fractures in the MIPPO group. These factors may have independently influenced fracture healing, infection rates, and functional outcomes, thereby introducing potential confounding. Similarly, concomitant fibular fixation was performed more frequently in the plating group and may have influenced fracture alignment and healing characteristics. Also,

the study included a relatively small sample of 30 patients, which was based on the number of eligible patients presenting during the study period rather than a formal sample size calculation. Consequently, the study may have been underpowered to detect differences in certain secondary outcomes. Owing to the limited sample size, subgroup analyses evaluating the independent effects of fracture pattern, comorbidities, and fibular fixation were not feasible. Future larger, adequately powered randomized studies with balanced baseline characteristics are warranted to validate these findings.

### **Conclusion**

IMIL nailing resulted in considerably better functional outcomes, quicker union time, shorter immobilisation and lower infection load compared to MIPPO plating for closed extra-articular AO 43-A distal third tibial fractures. The guide wire must be placed accurately and AP locking screws are important to avoid mal-alignment during nailing. MIPPO plating still remains a viable solution especially for comminuted fractures when nailing is technically difficult. Randomised controlled trials with bigger homogeneous samples are required for the ultimate establishment of the superiority of one technique over the other [20].

### **Statements and Declaration**

#### **Author Contributions**

BD has contributed to the conceptualization, design of the study, literature search, data acquisition, manuscript editing and review. BS contributed towards conceptualization, Statistical analysis, Manuscript review and editing. VK contributed towards literature search, data analysis, manuscript writing,

review and editing. BD acted as the corresponding author for this manuscript.

### **Conflicts of interest**

The authors declare that they do not have conflict of interest.

### **Funding**

No funding was received for conducting this study.

### **Ethical Approval**

Obtained approval from the Institutional Research Ethics Committee, Sri Ramachandra University (REF: CSP-MED/17/JAN/33/05)

### **References**

1. Boos N, Bugyi I. Results of locking intramedullary nailing in distal tibial shaft fractures. *Unfallchirurg.* 1989;92(9):453–458.
2. Fan CY, Chiang CC, Chuang TY, Chiu FY, Chen TH. Interlocking nails for displaced metaphyseal fractures of the distal tibia. *Injury.* 2005;36(5):669–674.
3. Gawali SR, Kukale SB, Nirvane PV, Toshniwal RO. Management of fractures of distal third tibia by interlock nailing. *J Foot Ankle Surg (Asia-Pacific).* 2016;3(1):15–22.
4. Ovadia DN, Beals RK. The fractures of the tibial plafond. *J Bone Joint Surg Am.* 1986;68(4):543–551.
5. Borg T, Larsson S, Lindsjö U. Percutaneous plating of distal tibial fractures. *Injury.* 2004;35(6):608–614.
6. Redfern DJ, Syed SU, Davies SJ. Fractures of the distal tibia: minimally invasive plate osteosynthesis. *Injury.* 2004;35(6):615–620.

7. Asif N, Siddiqui YS, Jain JK, Zahid M, Abbas M, Sabir AB, et al. Minimally invasive percutaneous plate osteosynthesis (MIPPO) in distal tibial fractures: a prospective study from developing nation. *J Trauma Treat.* 2014;S2:2–5.
8. Aksekili MA, Celik I, Arslan AK, Kalkan T, Ugurlu M. The results of minimally invasive percutaneous plate osteosynthesis (MIPPO) in distal and diaphyseal tibial fractures. *Acta Orthop Traumatol Turc.* 2012;46(3):161–167.
9. Collinge MD, Sanders RW. Minimally invasive plating of the distal tibial fractures. *J Orthop Trauma.* 2007;21(1):68–72.
10. Bone LB, Johnson KD. Treatment of tibial fractures by reaming and intramedullary nailing. *J Bone Joint Surg Am.* 1986;68(6):877–887.
11. Court-Brown CM, Christie J, McQueen MM. Closed intramedullary tibial nailing: its use in closed and type I open fractures. *J Bone Joint Surg Br.* 1990;72(4):605–611.
12. Krettek C, Schandelmaier P, Miclau T, Bertram R, Holmes W, Tschern H. Transarticular joint reconstruction and indirect plate osteosynthesis for complex distal supracondylar femoral fractures. *Injury.* 1997;28(Suppl 1):A31–41.
13. Im GI, Tae SK. Distal metaphyseal fractures of tibia: a prospective randomized trial of closed reduction and intramedullary nail versus open reduction and plate and screws fixation. *J Trauma.* 2005;59(5):1219–1223.
14. Vallier HA, Le TT, Bedi A. Radiographic and clinical comparisons of distal tibia shaft fractures (4 to 11 cm proximal to the plafond): plating versus intramedullary nailing. *J Orthop Trauma.* 2008;22(5):307–311.
15. Singh A, Kumar R, Ummat V, Pandey PK. Comparative study of minimally invasive plating versus nailing in distal tibia metaphyseal extra-articular fractures. *IOSR-JDMS.* 2017;16(9):5–9.
16. Mohamed AM, Abdelazeem AH, Abbas MF, Abdelazeem HM. Prospective study of distal tibia fractures treated with static reamed intramedullary nailing. *J Clin Orthop Trauma.* 2016;7(Suppl 1):88–93.
17. Natarajan GB, Srinivasan DK, Vijayaraghavan PV. Functional outcome of IMIL nailing versus MIPPO plating in distal third tibial fractures. *Int J Res Orthop.* 2017;3(5):1009–1012.
18. Nork SE, Schwartz AK, Agel J, Holt SK, Schrick JL, Winquist RA. Intramedullary nailing of distal metaphyseal tibial fractures. *J Bone Joint Surg Am.* 2005;87(6):1213–1221.
19. Attal R, Hansen M, Kirjavainen M, Bail H, Hammer TO, Rosenberger R, et al. A multicentre case series of tibia fractures treated with the Expert Tibia Nail (ETN). *Arch Orthop Trauma Surg.* 2012;132(7):975–984.
20. Janssen KW, Biert J, van Kampen A. Treatment of distal tibial fractures: plate versus nail: a retrospective outcome analysis of matched pairs of patients. *Int Orthop.* 2007;31(5):709–714.