



National Board of Examination - Journal of Medical Sciences
Volume 2, Issue 6, Pages 622–627, June 2024
DOI 10.61770/NBEJMS.2024.v02.i06.012

CASE REPORT

Phytobezoar (*Mangifera indica* seeds) induced Acute Small Bowel Obstruction: An Unusual Case

Kiratpal Singh Brar,¹ Dhiraj Kumar,² Sharad Syangden,³ Mahesh Kumar,³ Jashanpreet Singh,¹ Joe Nepram,¹ Ghaiyoor Ahmad,¹ Diwakar Kumar¹ and Kaushik Bhattacharya^{4,*}

¹*Surgery Postgraduate, Department of Surgery, Mata Gujri Memorial Medical College and LSK Hospital, Kishanganj - 855107, Bihar, India*

²*Professor, Department of Surgery, Mata Gujri Memorial Medical College and LSK Hospital, Kishanganj - 855107, Bihar, India*

³*Assistant Professor, Department of Surgery, Mata Gujri Memorial Medical College and LSK Hospital, Kishanganj - 855107, Bihar, India*

⁴*Associate Professor, Department of Surgery, Mata Gujri Memorial Medical College and LSK Hospital, Kishanganj - 855107, Bihar, India*

Accepted: 29-March-2024 / Published Online 07-June-2024

Abstract

Phytobezoar causing acute intestinal obstruction is a rare event. A case of accidental ingestion of mango seed causing intestinal obstruction is being reported requiring surgical intervention to extract the mango seed from the ileum. This condition must be kept in mind during the mango season while dealing with a case of intestinal obstruction in an emergency.

Keywords: Phytobezoar, Acute intestinal obstruction, Ileocecal valve

*Corresponding Author: Kaushik Bhattacharya
Email: kbhattacharya10@yahoo.com

Case Report

A 46-year-old male came to the emergency with severe central abdominal distension along with being unable to pass stool for 2 days and vomiting 2 -to 3 episodes per day. He gave a history of accidental ingestion of mango seed two days back. No other significant history was there, and vitals were stable except pulse rate being 120/minute. The abdomen was distended with features of intestinal obstruction. There were hyperperistaltic bowel sounds with per rectum examination being normal. The patient was dehydrated. X-rays showed multiple dilated small intestinal loops and the ultrasound abdomen showed multiple dilated small bowels with inter-bowel free fluids, suggestive of acute intestinal obstruction (Figure 1). After initial resuscitation, the patient underwent

emergent exploratory laparotomy through a midline incision. Dilated loops of the ileum were seen with mild free fluid. On tracing the small intestine, a foreign body of 10cm in length and 6 cm in width was felt approximately 20 cm from the ileocecal valve. The distal bowel collapsed, a longitudinal enterotomy was done and the foreign body was extracted which turned out to be a mango seed (Figure 2). The bowel decompression was done, and a temporary loop ileostomy was done (Figure 3). The patient had an uneventful postoperative course and was discharged in stable condition on the 7th postoperative day. Stoma bag care was taught to the patient and his relatives with advice to follow up after 6 weeks (Figure 4).

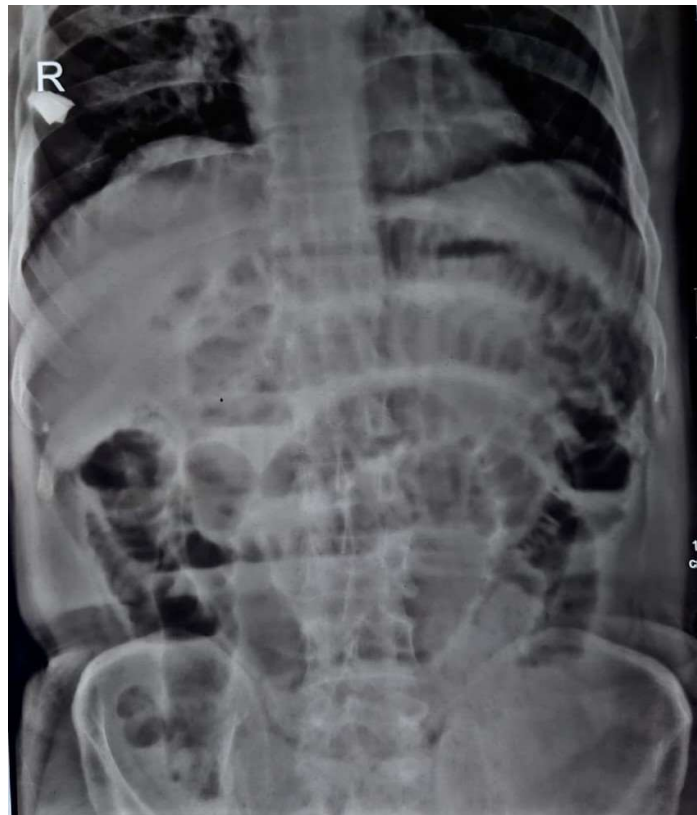

Figure 1. X Ray abdomen showing dilated intestinal loops.

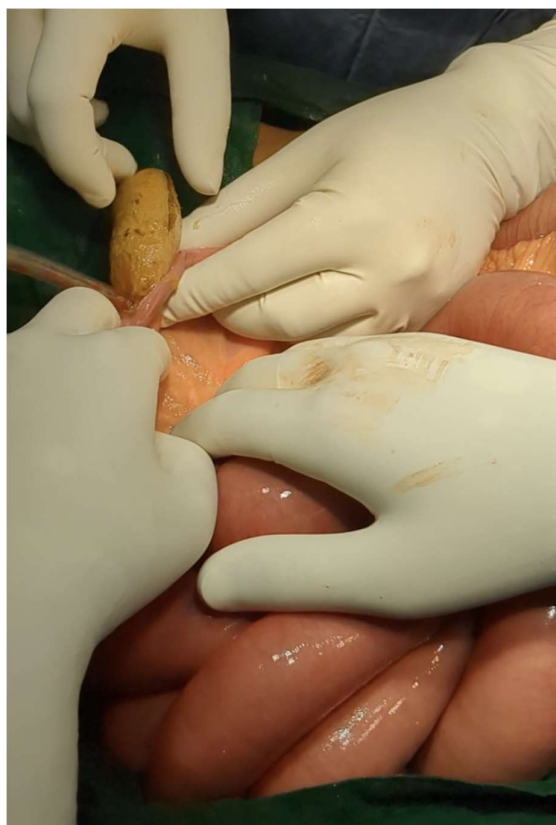

Figure 2. Mango seed getting extracted through enterotomy.

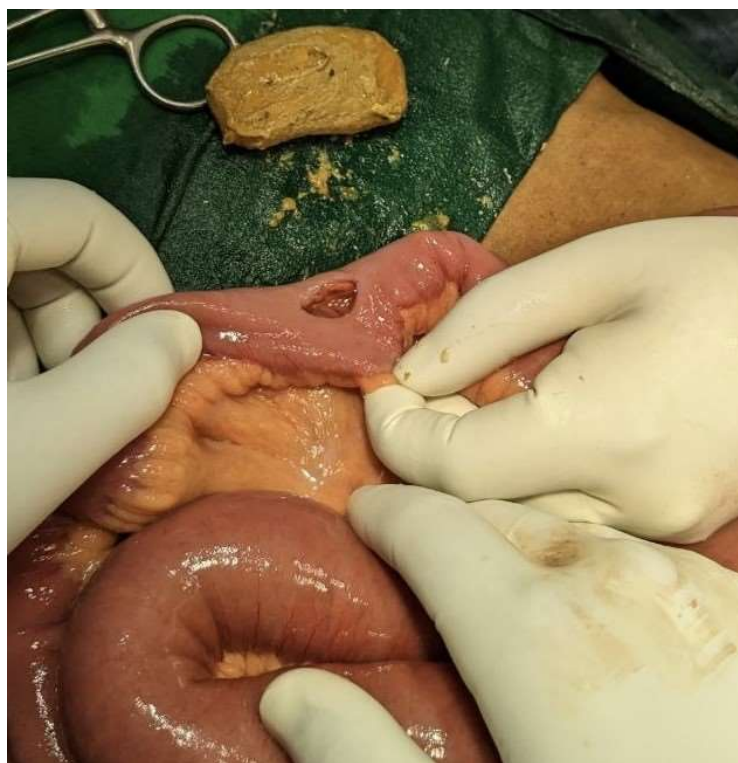


Figure 3. Enterotomy wound and the mango seed.



Figure 4. The phytobezoar mango seed 10 cm in length and 6 cm in breadth.

Discussion

Phytobezoar causing acute intestinal obstruction is a rare event and a mango seed ingested accidentally causing bowel obstruction is an even rarer case. Even though the foreign body that reaches the stomach has an 80–90% chance of passage, mango seed had a width making it impossible through the ileocecal valve [1].

The phytobezoar-induced obstruction typically occurs 50–70 cm from the ileocecal valve as the luminal diameter becomes narrow, and the luminal content viscosity increases due to decreased intestinal absorption. The most common risk factors associated with the formation of phytobezoar are history of past surgery, intake of a high fiber diets, and other

morbid conditions like psychiatric disease, dysmotility, diabetes mellitus with autonomic neuropathy, hypothyroidism, problem with mastication due to dental issues, and generalized frail person with myotonic dystrophy. There are few very interesting reports of small bowel obstruction caused by mango seed lodged within a Meckel's diverticulum [2]. As exploratory laparotomy has been the traditional gold standard procedure for acute intestinal obstruction when surgical intervention is necessary, diagnostic laparoscopy followed by therapeutic laparoscopic intervention can also be useful in the diagnosis and treatment of intestinal phytobezoar. Studies are showing Coca-Cola combined with endoscopic techniques being used effectively to treat gastric phytobezoar and avoid surgery [3]. The preventive measures mentioned to prevent such a complication from occurring are a low-fiber diet, more water, proper mastication, and treatment of gastrointestinal motility disorders [4]. Recent literature has recommended timely ingestion of Coca-Cola (2000-4000 mL per day for 7 days) yields significant benefits, including a complete dissolution rate of 100%, a low incidence of gastric ulcers, no need for fragmentation by surgical intervention, and is cost-effective, especially in patients with gastric phytobezoar [5]. There are not many reports from India on this condition in the literature even though such incidents keep happening. Apart from small bowel obstruction, mango seed has also been associated very rarely with large gut obstruction [6].

In conclusion, mango seed causing acute intestinal obstruction is not a common phenomenon but every patient who develops features of intestinal

obstruction during the mango season needs to have phytobezoar as a differential diagnosis, as a cause behind this surgical emergency.

Statements and Declarations

Conflicts of interest

The authors declares that they do not have conflict of interest.

Funding

No funding was received for conducting this study.

References

1. Fernando AR, Bulathsinghela R, Samarasekera DN. An unusual cause of small bowel obstruction due to an ingested mango seed: a case report. *BMC Res Notes*. 2017 Nov 2;10(1):549. doi: 10.1186/s13104-017-2875-3.
2. Hulf T, Ben-David M. Small bowel obstruction caused by a mango phytobezoar within a Meckel's diverticulum. *J Surg Case Rep*. 2023 Nov 11;2023(11):rjad613. doi: 10.1093/jscr/rjad613.
3. Sasmal PK, Rath S, Meher S, et al. Phytobezoar (*Mangifera Indica* Seeds) induced acute intestinal obstruction. *MOJ Clin Med Case Rep*. 2016;5(1):179-181. DOI: [10.15406/mojcr.2016.05.00122](https://doi.org/10.15406/mojcr.2016.05.00122)
4. Bouali M, Ballati A, El Bakouri A, Elhattabi K, Bensardi F, Fadil A. Phytobezoar: An unusual cause of small bowel obstruction. *Ann Med Surg (Lond)*. 2021 Jan 25;62:323-325. doi: 10.1016/j.amsu.2021.01.048.

5. Liu FG, Meng DF, Shen X, Meng D, Liu Y, Zhang LY. Coca-Cola consumption vs fragmentation in the management of patients with phytobezoars: A prospective randomized controlled trial. *World J Gastrointest Endosc.* 2024 Feb 16;16(2):83-90. doi: 10.4253/wjge.v16.i2.83.
6. Islam S, Saroop S, Bheem V, Harnarayan P, Naraynsingh V. Mango seed causing acute large bowel obstruction in descending colon-world's first reported case. *Int J Surg Case Rep.* 2018;51:125-129. doi: 10.1016/j.ijscr.2018.08.028. Epub 2018 Aug 19.