



National Board of Examination - Journal of Medical Sciences  
Volume 1, Issue 8, Pages 541–548, August 2023  
DOI 10.61770/NBEJMS.2023.v01.i08.007

## CASE REPORT

### **Sjogrens Syndrome Presenting as a Case of Cerebro Vasular Accident with Thrombocytopenia – A Case Report**

Deepak S. Laddhad<sup>1</sup>, Rushikesh Subhash Joshi<sup>2</sup>, Bantu Ruthvick<sup>3,\*</sup> and Shantanu Deepak Laddhad<sup>4</sup>

<sup>1</sup>Senior Consultant, DNB Guide, Laddhad Hospital, Wankhede Lay Out Buldana, Maharashtra 443001, India

<sup>2</sup>Assistant Professor Department of Neurology Seth GS Medical College and KEM Hospital, Mumbai.

<sup>3</sup>DNB Medicine, Laddhad Hospital, Wankhede Lay Out, Buldana, Maharashtra, India. 443001

<sup>4</sup>King Edward Memorial (KEM) Hospital, Acharya Donde, Marg, Parel East, Parel, Mumbai, Maharashtra 400012, India.

Accepted: 01-July-2023 / Published Online: 04-August-2023

#### **Abstract**

Auto immune disorders have a wide range of presentations. Often, they are missed due to difference in their spectrum of presentations. Hence any slight suspicion of autoimmunity should be thoroughly ruled out. Multiple system involvement like joints, renal, vascular events simultaneously presenting should always rise a suspicion of autoimmunity and prompt investigations should be paged that could be effectively contributing to decrease mortality and morbidity of the patient. Thorough history, if possible, pedigree charts should be evaluated for any clues of autoimmunity. All first-degree relatives of the patient should also be evaluated for any possibility of autoimmune diseases.

**Keywords:** Autoimmune diseases, Sjogren's syndrome, Acute cortical infarct, Thrombocytopenia

\*Corresponding author: Bantu Ruthvick  
Email: ruthvickbantu@gmail.com

## Abbreviations

SS-A, B ANTIBODIES – ANTI SJOGRENS SYNDROME RELATED ANTIGEN A, B ANTIBODIES

OPD – OUT PATIENT DEPARTMENT

BP – BLOOD PRESSURE

HB – HEMOGLOBIN

LMWH – LOW MOLECULAR WEIGHT HEPARIN

CVE – CEREBRO VASULAR EPISODE

AFI – ACUTE FEBRILE ILLNESS

SLE – SYSTEMIC LUPUS ERYTHEMATOSUS

ITP – IMMUNE THROMBOCYTOPENIA

RTA – RENAL TUBULAR ACIDOSIS

## Introduction

Sjogren's syndrome is an autoimmune disorder with lymphocytic infiltration of exocrine glands most commonly involving salivary and lacrimal glands. Female are affected more than males at ratio of 20:1 [1].

Patients usually present with dryness of mouth and dry eyes. Extra glandular symptoms like fatigue, arthritis, weight loss. It might also present with proximal myopathy, peripheral neuropathy, and interstitial lung disease.

Pan cytopenic picture might be seen on haematological examination. SS-A, SS-B antibodies will be seen in 40- 80% cases. Diagnosis is mostly based on clinical and immunological analysis.

Steroids, higher immunosuppressants like rituximab, cyclophosphamide have promising role in treatment of Sjogren's syndrome.

## Case Presentation

A 50-year-old female came to opd with chief complaint of generalized weakness, fatigue, vomiting, nausea, low appetite since last one week. Nausea is persistent whole day and increasing on food intake. Patient had 2–3 episodes of

vomiting which are non-blood or bile stained, non-projectile and mostly contain food and mucous. Patient has severe fatigue, not interested to do any work or house hold activity. Patient had an episode of acute febrile illness one month back for which patient for hospitalised for three to five days.

Patient is a known case of hypothyroidism has been using medication for the same (eltroxin 75 mg). Patient was once diagnosed with hypertension and was not adherent to her medication. No significant family history has been found. Patient reached menopause 3 years back. No addictions. Normal bowel and bladder movement.

On admission pulse – 84/ minute, BP – 138/84 mm/hg right hand supine position. Oxygen saturation – 99% on room air. Patient is pale but no cyanosis, rash, lymphadenopathy, clubbing, icterus seen. Mild periorbital oedema seen.

On systemic examination no significant findings are seen.

Laboratory investigations revealed hb- 10.5gm/dl, TLC – 8000 gm/dl, platelets – 36000 / cumm. Serum bilirubin – 1.80 mg/dl, direct bilirubin – 0.35 mg/dl, indirect bilirubin – 1.45 mg/dl. Patient has

normal blood sugars. Urine routine revealed turbid appearance, 4+ albumin, 8-10pus cells. Blood urea – 78 mg/dl, bun – 36 mg/dl, serum creatinine 1.5 mg/dl.

Ultrasound abdomen has shown bilateral increased cortical echogenicity with poor corticomedullary differentiation and perirenal fluid collection with 19\*16mm cortical cyst. Echocardiography revealed presence of bicuspid aortic valve.

Next day morning around 4:00 am patient had severe weakness on right side upper and lower limb, patient is aphasic, right sided mouth deviation seen. MRI shown acute non haemorrhagic cortical infarct in bilateral occipital lobe more on left lobe. Repeat platelet count shown a value of 9000 /cumm.

Patient has been treated with antibiotics, fresh frozen plasma, platelet concentrates, LMWH, anti-platelets and thyroid supplements.

There is no much rise in platelet count even after platelet concentrate transfusion and subsequent development of CVE along with the presence of 4+ proteinuria, has led to suspicion of autoimmune disorder and hence antibody panel has been sent. SS-A, Ro 52KD, SS-B are found to be positive.

Patient has been treated with steroids, antibiotics, fresh frozen plasma, platelet concentrates, LMWH, anti-platelets and thyroid supplements.

Repeat platelet shown a value of 13000/cumm on day three. Patient has been questioned about symptoms of Sjogren's syndrome and then she revealed lack proper salivation while eating from many months.

Even though patient is still in recovery, on request of the relative's, patient has been referred to another hospital near their hometown.

## Discussion

We present a case of 50-year women with Sjogren's syndrome who presented with chief complaint of generalized weakness, fatigue, vomiting, nausea, low appetite, thrombocytopenia in the last one week and subsequently developed stroke. Initially patient is thought to be a case of thrombocytopenia post-acute febrile illness as patient has a history of AFI one month back.

In Sjogren's syndrome patient with anti-Ro antibodies present with higher frequency of systemic manifestations and haematological alterations like anemia and thrombocytopenia [1]. In autoimmune disorders like SLE, Sjogren's with ITP there will be circulating auto antibodies causing peripheral destruction of platelets leading to thrombocytopenia [2].

Type 2 mixed cryoglobulinemia associated with Sjogren's syndrome may lead to peripheral neuropathy, Raynaud's phenomenon, and renal injury. Purpura and arthralgia might also be seen [3].

The management of Sjogren's syndrome mainly focusses on dryness of eyes and oral cavity. Patient should be given lacrimal supplements like hydroxy methyl cellulose, polyvinyl alcohol, hypo tears. Patient should be encouraged to take more fluids. Topical anti-inflammatory solutions with cyclosporine are shown to be promising in some studies [4]. Pilocarpine and cevimeline can be used to stimulate oral secretions.

Renal manifestations like RTA can be treated with soda bicarbonate. Glucocorticoids and monoclonal antibodies like rituximab (anti CD 20) are effective in controlling manifestations of the disease by partial depletion of B cells in salivary glands [5] (Figures 1 to 4).

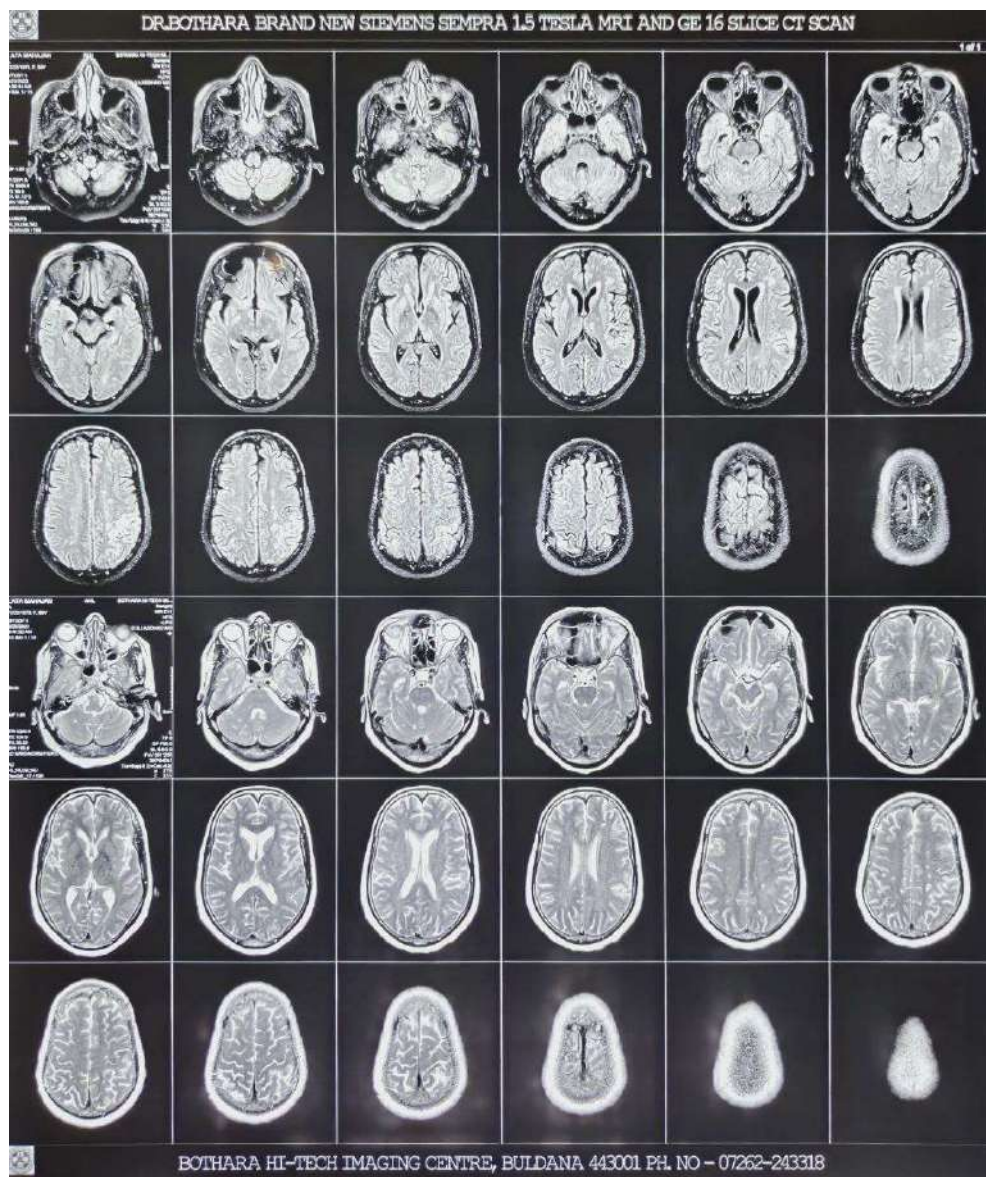

Figure 1. T1 weighted MRI with flair axial with lower T2.

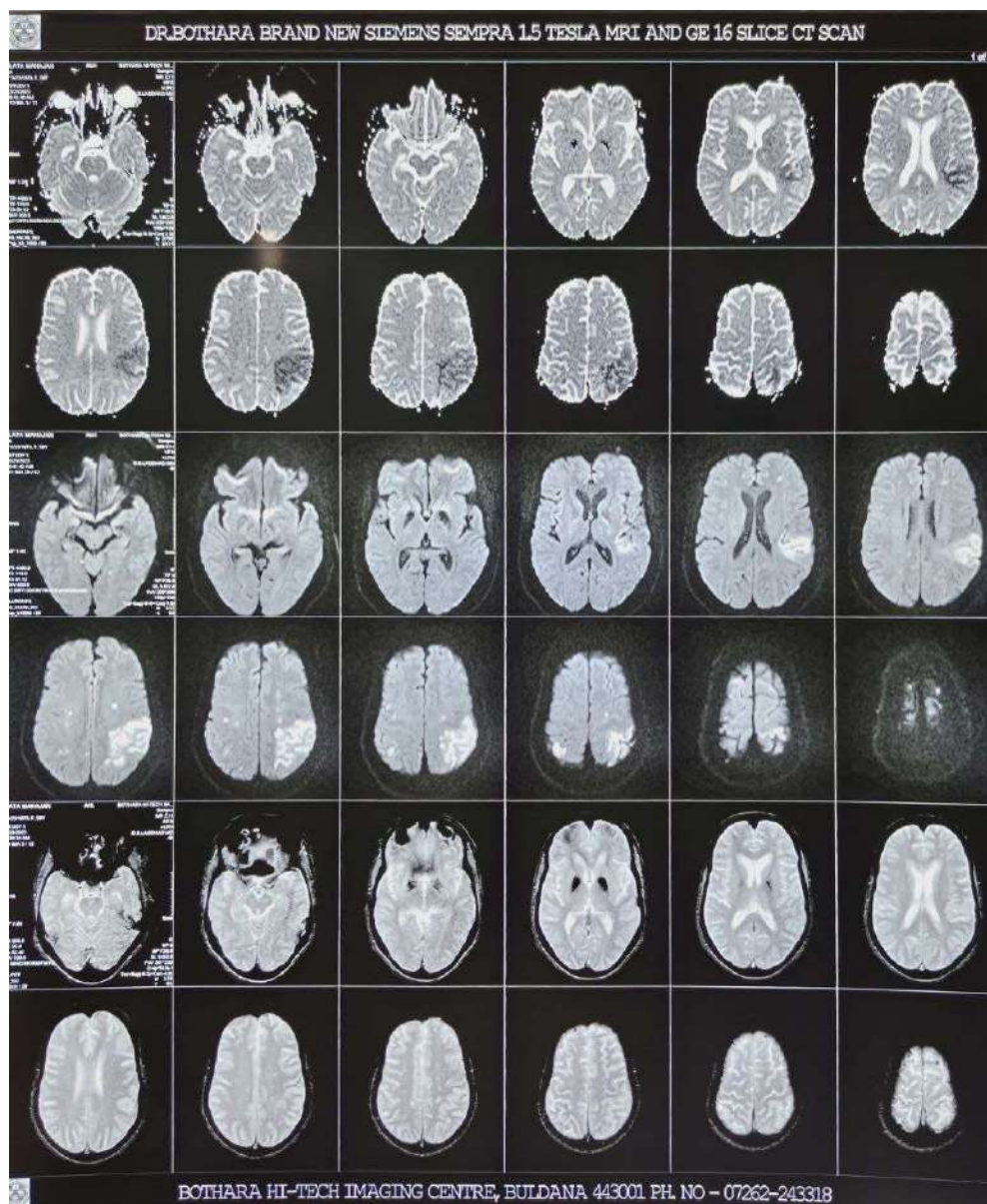


Figure 2. MRI with dwi/swi/gre sequencing.

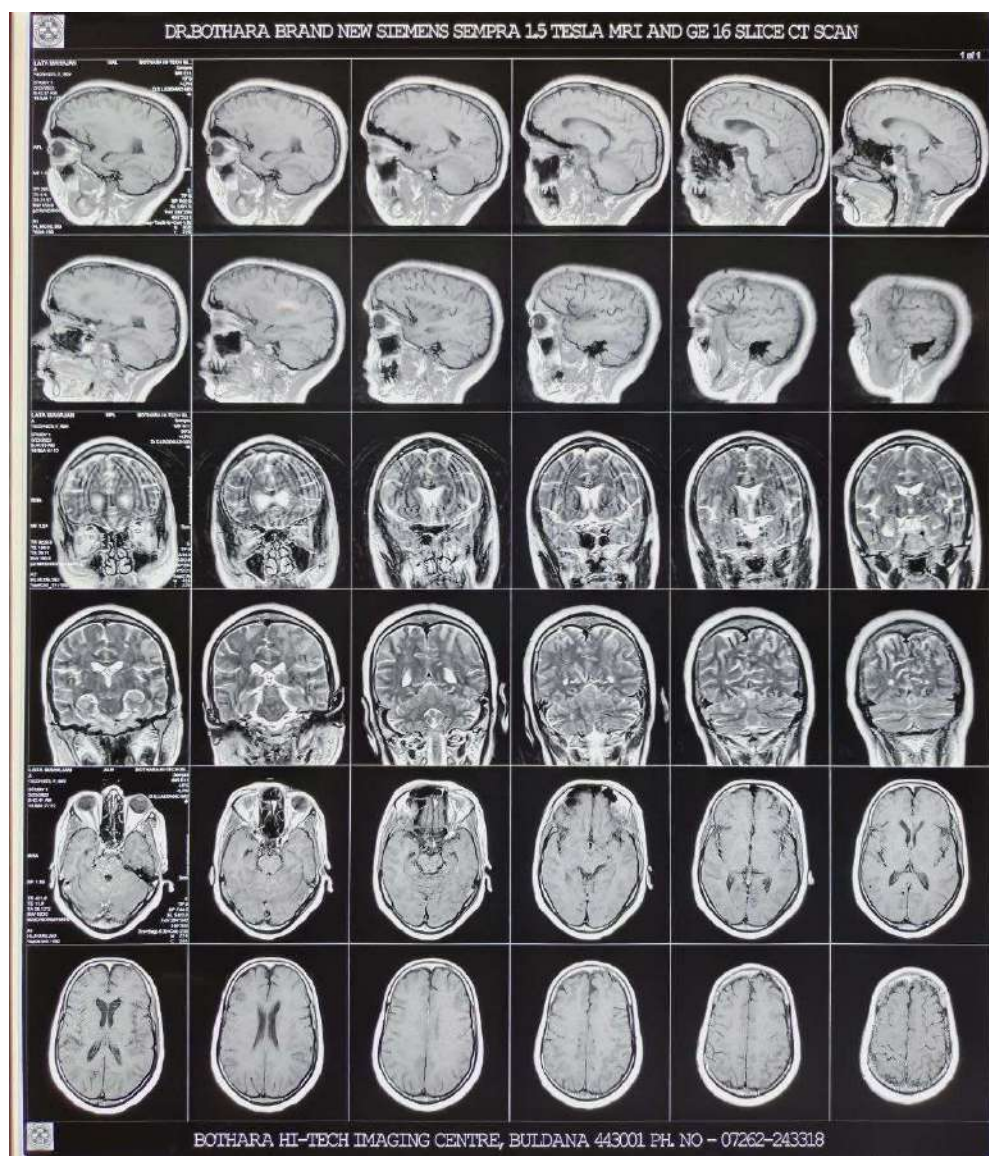


Figure 3. T2 SEQ with axial T1.



Figure 4. MR venogram.

## Conclusion

Auto immune disorders have a wide range of presentations. Hence any slight suspicion of autoimmunity should be thoroughly ruled out. Multiple system involvement like joints, renal, vascular events simultaneously presenting should always rise a suspicion of autoimmunity and prompt investigations should be paged that could be effectively contributing to decrease mortality and morbidity of the patient.

## Statements and Declarations

We declare that we have no financial interests or funding for this case report. This has been done only as a part of academical interest.

## References

1. Autrel-Moignet A, Lamy T. Autoimmune neutropenia. *Presse Med.* 2014;43:e105-18.
2. D. S. Beardsley, "Pathophysiology of immune thrombocytopenic purpura," *Blood Reviews*, vol. 16, no. 1, pp. 13–14, 2002.
3. Martínez VA, Leal CA, Moreno DC. Alteraciones hematológicas como manifestación inicial del síndrome de Sjögren primario. *Rev Colomb Reumatol.* 2018;25:55–58.
4. Leonardi A, Van Setten G, Amrane M, Ismail D, Garrigue JS, Figueiredo FC, Baudouin C. Efficacy and safety of 0.1% cyclosporine A cationic emulsion in the treatment of severe dry eye disease: a multicenter randomized trial. *Eur J Ophthalmol.* 2016 Jun 10;26(4):287-96. doi: 10.5301/ejo.5000779. Epub 2016 Apr 7. PMID: 27055414.
5. Pijpe J, Meijer JM, Bootsma H, van der Wal JE, Spijkervet FK, Kallenberg CG, Vissink A, Ihrler S. Clinical and histologic evidence of salivary gland restoration supports the efficacy of rituximab treatment in Sjögren's syndrome. *Arthritis Rheum.* 2009 Nov;60(11):3251-6. doi: 10.1002/art.24903. PMID: 19877054

## Author Contributions

Deepak Laddhad: final review and approval of the study; Rushikesh Subash Joshi; final review and approval of the study; Ruthvick Bantu: Reviews of literature, detailing the study; Shantanu Deepak Laddhad: Reviews of literature, detailing the study

## Conflict of interest

The authors declare that they have no competing interests.

## Ethics approval, Consent to participate, Consent to publish, Availability of data and material, Code availability

Not applicable.