



ORIGINAL ARTICLE

**Temporal Evolution of CT Findings in COVID-19 Patients: An Observational Study**

Chandra Kumar C,<sup>1</sup> Priya Narayanasamy,<sup>2</sup> Jeevithan Shanmugam<sup>3</sup> and Kumarasampath Marimuthu<sup>2,\*</sup>

<sup>1</sup>*Junior Consultant, Aarthi Scans, Chennai*

<sup>2</sup>*Senior Consultant, Dr Kamakshi Memorial Hospital, Chennai- 600100*

<sup>3</sup>*Professor in Community Medicine, KMCH Institute of Health Sciences and Research, Coimbatore 641045*

Accepted: 09-July-2024 / Published Online 04-August-2024

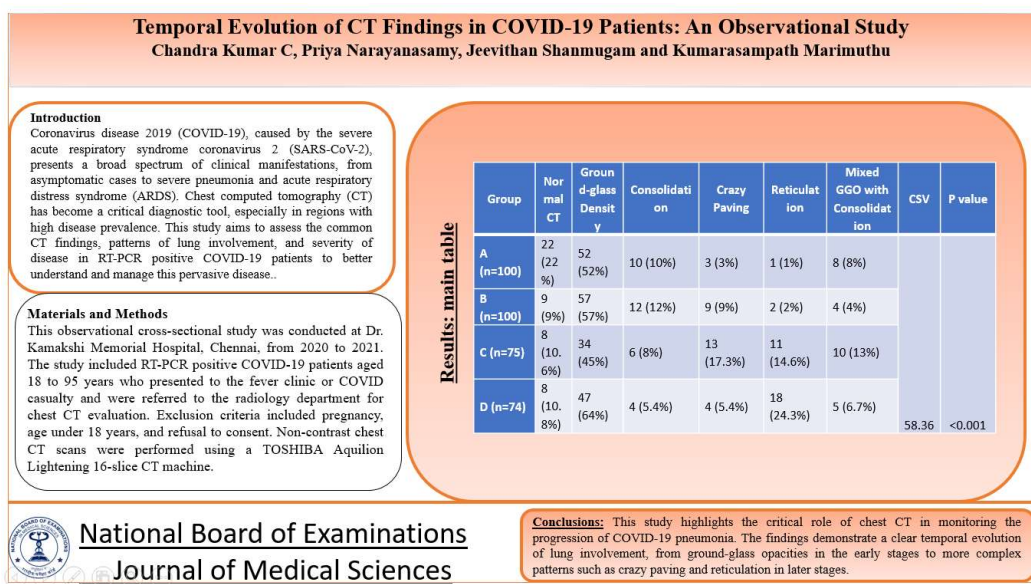
**Abstract**

**Introduction:** Coronavirus disease 2019 (COVID-19), caused by the severe acute respiratory syndrome coronavirus 2 (SARS-CoV-2), presents a broad spectrum of clinical manifestations, from asymptomatic cases to severe pneumonia and acute respiratory distress syndrome (ARDS). Chest computed tomography (CT) has become a critical diagnostic tool, especially in regions with high disease prevalence. This study aims to assess the common CT findings, patterns of lung involvement, and severity of disease in RT-PCR positive COVID-19 patients to better understand and manage this pervasive disease. **Materials and Methods:** This observational cross-sectional study was conducted at Dr. Kamakshi Memorial Hospital, Chennai, from 2020 to 2021. The study included RT-PCR positive COVID-19 patients aged 18 to 95 years who presented to the fever clinic or COVID casualty and were referred to the radiology department for chest CT evaluation. Exclusion criteria included pregnancy, age under 18 years, and refusal to consent. Non-contrast chest CT scans were performed using a TOSHIBA Aquilion Lightening 16-slice CT machine. Scans were acquired in a single inspiratory breath-hold from the lung apex to the costophrenic angle. CT findings were analyzed and reported by two experienced radiologists, with discrepancies resolved through consensus. **Results:** Out of 349 patients, 213 (61%) were male and 136 (39%) were female, with a mean age of 47.7 years. The distribution of CT findings showed significant variability among the four groups. Group A had the highest percentage of normal CT scans (22%) and ground-glass opacities (52%). Group B exhibited a reduction in normal CT scans (9%) and an increase in ground-glass opacities (57%). Group C showed further decrease in normal CT scans (10.6%) with increased crazy paving (17.3%) and reticulation (14.6%). Group D had similar normal CT scans (10.8%) but significantly higher incidences of reticulation (24.3%) and ground-glass opacities (64%). **Conclusion:** This study highlights the critical role of chest CT in monitoring the progression of COVID-19 pneumonia. The findings demonstrate a clear temporal evolution of lung involvement, from ground-glass opacities in the early stages to more complex patterns such as crazy paving and reticulation in later stages.

**Keywords:** COVID-19, Chest CT, Ground-glass opacities, Lung involvement, Disease progression

\*Corresponding Author: Kumarasampath Marimuthu  
Email: doctorsambath@gmail.com

## Graphical Abstract

**Introduction**

Coronavirus disease 2019 (COVID-19), caused by the severe acute respiratory syndrome coronavirus 2 (SARS-CoV-2), emerged in Wuhan, China, at the end of 2019 and rapidly escalated into a global pandemic. SARS-CoV-2 is an enveloped single-stranded RNA virus that leads to a spectrum of clinical manifestations, ranging from asymptomatic cases to severe pneumonia and acute respiratory distress syndrome (ARDS) [1-3]. The disease's incubation period ranges from 1 to 14 days, with a mean duration of 5 to 7 days, and peak viral shedding occurring before symptom onset, underscoring the potential for transmission from asymptomatic individuals [4-6].

Common symptoms include fever (80-90%), cough (60-80%), and dyspnea (18-46%), with other possible symptoms such as myalgia, fatigue, sore throat, nasal congestion, headache, nausea, vomiting, and diarrhea [7,8]. Diagnosis primarily relies on clinical symptoms and a positive reverse-transcription polymerase chain reaction (RT-PCR) assay [9]. The case

fatality rate is higher in patients with comorbidities such as cardiovascular disease, diabetes, chronic respiratory disease, systemic hypertension, and cancer [10].

Chest computed tomography (CT) has become a critical tool for diagnosing and managing COVID-19, especially in regions with high disease prevalence. Typical CT findings include ground-glass opacities, consolidation, and patterns of bilateral and peripheral distribution [11]. Studies have shown that chest CT has a high sensitivity for detecting COVID-19 pneumonia, making it a valuable diagnostic tool, particularly in epidemic areas where rapid diagnosis and isolation are crucial [12, 13]. This study aims to assess the common CT findings, patterns of lung involvement, and severity of disease in RT-PCR positive COVID-19 patients, contributing to better understanding and management of this pervasive disease.

**Materials and Methods**

This observational cross-sectional study was conducted at Dr. Kamakshi

Memorial Hospital, Chennai, from 2020 to 2021. The study included RT-PCR positive COVID-19 patients aged 18 to 95 years who presented to the fever clinic or COVID casualty and were referred to the radiology department for chest CT evaluation. Patients were excluded if they were pregnant, under 18 years, or refused consent.

Non-contrast chest CT scans were performed using a TOSHIBA Aquilion Lightning 16-slice CT machine. Scans were acquired in a single inspiratory breath-hold from the lung apex to the costophrenic angle. Images were reconstructed into 1 mm thick slices and viewed in both lung and mediastinal windows. CT findings were analyzed and reported by two experienced radiologists. Disparities in reports were resolved through consensus.

Patients were categorized into four groups based on the day of presentation since symptom onset: Group A (1-7 days), Group B (8-14 days), Group C (15-21 days), and Group D (22-28 days). The CT images were evaluated for types of lung opacities, laterality, pattern of distribution, lobar involvement, and additional findings. Severity of lung involvement was assessed using a CT severity score based on the percentage area involved in each lobe.

## Results

Out of 349 patients, 213 (61%) were male and 136 (39%) were female, with a mean age of 47.7 years. Table 1 shows the distribution of CT findings among the four groups of COVID-19 patients shows significant variability. Group A, consisting of patients in the first week of illness, had 22% with normal CT scans, 52% with ground-glass opacities, and lower incidences of other findings. Group B, patients in the second week, exhibited a reduction in normal CT scans to 9%, with a

slight increase in ground-glass opacities (57%) and other findings. Group C, representing the third week of illness, showed a further decrease in normal CT scans (10.6%), with increased crazy paving (17.3%) and reticulation (14.6%). Group D, patients in the fourth week, had similar levels of normal CT scans (10.8%) but significantly higher incidences of reticulation (24.3%) and ground-glass opacities (64%). The statistically significant result suggests a clear progression and evolution of lung involvement in COVID-19 patients as the disease advances, highlighting the importance of CT scans in monitoring and managing the disease over time.

The distribution of presenting symptoms among the four groups of COVID-19 patients (Table 2) shows significant variability. Group A, consisting of patients in the first week of illness, had the highest percentage of fever (77.3%) and cough (60.0%), with lower incidences of dyspnea (18.0%) and other symptoms. Group B, patients in the second week, exhibited a slight increase in symptoms like fever (83.0%) and cough (80.0%), with a significant increase in dyspnea (46.0%) and sore throat (30.0%). Group C, representing the third week of illness, showed the highest incidence of dyspnea (70.0%) and sore throat (40.0%). Group D, patients in the fourth week, had a significant reduction in fever (24.3%) but an increased percentage of reticulation (24.3%) and lower incidences of other symptoms. The result is statistically significant. This suggests that the progression and presentation of symptoms in COVID-19 patients vary significantly over the course of the disease, highlighting the importance of continuous monitoring and tailored management strategies for different stages of the illness.

Table 1. Distribution of study population according to presence of CT findings

Group	Normal CT	Ground-glass Density	Consolidation	Crazy Paving	Reticulation	Mixed GGO with Consolidation	CSV	P value
A (n=100)	22 (22%)	52 (52%)	10 (10%)	3 (3%)	1 (1%)	8 (8%)	58.36	<0.001
B (n=100)	9 (9%)	57 (57%)	12 (12%)	9 (9%)	2 (2%)	4 (4%)		
C (n=75)	8 (10.6%)	34 (45%)	6 (8%)	13 (17.3%)	11 (14.6%)	10 (13%)		
D (n=74)	8 (10.8%)	47 (64%)	4 (5.4%)	4 (5.4%)	18 (24.3%)	5 (6.7%)		

Table 2. Distribution of symptoms with respect to duration

Symptom	Group A (n=100)	Group B (n=100)	Group C (n=75)	Group D (n=74)	CSV	P value
Fever	77 (77.3%)	83 (83.0%)	67 (88.8%)	18 (24.3%)	68.3	<0.001
Cough	60 (60.0%)	80 (80.0%)	50 (67.0%)	37 (50.0%)		
Dyspnea	18 (18.0%)	46 (46.0%)	52 (70.0%)	24 (33.0%)		
Myalgia/Fatigue	52 (52.0%)	47 (47.0%)	34 (45.0%)	18 (24.0%)		
Sore Throat	15 (15.0%)	30 (30.0%)	30 (40.0%)	7 (10.0%)		
Headache	18 (18.0%)	20 (20.0%)	22 (30.0%)	11 (15.0%)		
Nausea/Vomiting	5 (5.0%)	10 (10.0%)	15 (20.0%)	9 (12.0%)		
Diarrhea	4 (4.0%)	9 (9.0%)	9 (12.0%)	6 (8.0%)		
Loss of Smell/Taste	12 (12.0%)	15 (15.0%)	7 (10.0%)	4 (6.0%)		

The distribution of severity of lung involvement among the four groups of COVID-19 patients shows significant variability (Table 3). Group A, consisting of patients in the first week of illness, had the highest percentage of mild cases (54%) and no severe cases (0%). Group B, patients in the second week, exhibited a similar percentage of mild cases (53%) but had a higher percentage of moderate (34%) and severe cases (5%). Group C, representing the third week of illness, showed a lower percentage of mild cases (32%) but the highest percentage of severe cases (24%). Group D, patients in the fourth week, had an intermediate percentage of mild cases (48.6%) and a lower percentage of severe cases (8.1%) compared to Group C. The severity of lung involvement in COVID-19 patients varies significantly over the course of the disease, with an increase in severity observed in the later stages of the illness. The results are statistically significant. However the distribution of lobar

involvement among the four groups of COVID-19 patients shows mild variability but does not reach statistical significance.

The mean CT severity score increases from Group A (first week of illness) to Group C (third week of illness), indicating a progression in the severity of lung involvement as the disease advances. Group D (fourth week of illness) shows a slight decrease in the mean CT severity score compared to Group C, possibly indicating the beginning of a resolution phase or the effects of medical intervention. The differences in mean CT severity scores among the groups are statistically significant. This suggests that the severity of lung involvement, as measured by CT severity scores, varies significantly over the course of the disease highlighting the importance of monitoring CT severity scores to assess the progression and management of COVID-19 pneumonia (Table 4).

Table 3. Association between CTSS score and Duration

Group	Mild (CTSS < 8)	Moderate (CTSS 9-15)	Severe (CTSS > 15)	CSV	P value
A (n=100)	54 (54%)	24 (24%)	0 (0%)	42.29	<0.001
B (n=100)	53 (53%)	34 (34%)	5 (5%)		
C (n=75)	24 (32%)	25 (33.3%)	18 (24%)		
D (n=74)	36 (48.6%)	19 (25.6%)	6 (8.1%)		

Table 4. Association between CT severity and duration

Group	Mean CT Severity Score	Standard Deviation	F value	P value
A (n=100)	4.9	4.1	9.33	< 0.001
B (n=100)	7.4	4.7		
C (n=75)	10.4	6.9		
D (n=74)	6.9	6.2		

### Discussion

This study provides a detailed analysis of CT findings in COVID-19 patients, highlighting the progression and patterns of lung involvement over the course of the disease. In the early stages (Group A), ground-glass opacities were the predominant finding, while later stages (Groups B and C) showed an increase in consolidation, crazy paving patterns, and reticulations. The findings align with previous studies that reported similar CT manifestations in COVID-19 patients [14-16]. Bilateral lung involvement with a peripheral and posterior distribution was common across all groups, with a notable lower lobe predilection. This distribution pattern is consistent with the literature, which emphasizes the typical peripheral subpleural involvement in COVID-19 pneumonia [17].

The predominant findings of ground-glass opacities and their peripheral distribution align with the results of previous studies by Yoon et al. [18] and Cheng et al. [19], which reported similar CT features in COVID-19 patients. The observed progression from ground-glass opacities to crazy paving and reticulation patterns corresponds with findings from Wang et al. [20], indicating a typical

temporal evolution of CT changes in COVID-19 pneumonia.

The presence of bilateral involvement and lower lobe predilection is consistent with the systematic review by Ojha et al. [21], which found a high incidence of bilateral and peripheral lung involvement. The occurrence of consolidation and mixed patterns, particularly in the second and third weeks of illness, parallels the findings of Zhao et al. [22], who noted similar patterns in their multicenter study.

The study also corroborates the high sensitivity of chest CT in detecting COVID-19 pneumonia, as demonstrated by Ai et al. [12], who reported a sensitivity of 97% for chest CT compared to RT-PCR. This emphasizes the utility of chest CT as a rapid and effective diagnostic tool, especially in epidemic settings where timely isolation and treatment are critical.

In comparison to early-phase disease, the advanced-phase disease was characterized by increased frequencies of consolidation, crazy paving patterns, and reticulation. This pattern of progression from ground-glass opacities to more complex lesions has been observed in other studies, such as those by Pan et al. [23] and Xu et al. [24], supporting the notion that CT findings can provide valuable insights into

the temporal evolution of lung involvement in COVID-19 patients.

Moreover, the severity of lung involvement as assessed by the CT severity score (CTSS) in this study showed a clear correlation with the clinical severity of the disease. Similar correlations between CTSS and clinical severity have been reported by Francone et al. [25] and Li et al. [26], suggesting that CTSS could be a useful parameter for risk stratification and management of COVID-19 patients.

### **Conclusion**

This study highlights the critical role of chest CT in monitoring the progression of COVID-19 pneumonia. The findings demonstrate a clear temporal evolution of lung involvement, from ground-glass opacities in the early stages to more complex patterns such as crazy paving and reticulation in later stages. The significant correlation between CT severity scores and clinical severity underscores the potential of CT as a valuable tool for risk stratification and management of COVID-19 patients. These insights can aid clinicians in making informed decisions regarding patient care. Future research with larger sample sizes and longitudinal follow-up will be essential to further validate these findings and explore the long-term implications of COVID-19 on lung health.

### **Statements and Declarations**

#### **Conflicts of interest**

The authors declares that they do not have conflict of interest.

#### **Funding**

No funding was received for conducting this study.

### **Human and animal rights**

This article does not contain any studies with human participants or animals performed by any of the authors.

### **References**

1. Chen Y, Li L. SARS-CoV-2: virus dynamics and host response. *Lancet Infect Dis.* 2020 Mar.
2. Huang C, Wang Y, Li X, et al. Clinical features of patients infected with 2019 novel coronavirus in Wuhan, China. *Lancet.* 2020;395(10223):497-506.
3. World Health Organization. Naming the coronavirus disease (COVID-2019) and the virus that causes it. 2020.
4. Guo YR, Cao QD, Hong ZS, et al. The origin, transmission and clinical therapies on coronavirus disease 2019 (COVID-19) outbreak - An update on the status. *Mil Med Res.* 2020;7:11.
5. Anderson RM, Heesterbeek H, Klinkenberg D, Hollingsworth TD. How will country-based mitigation measures influence the course of the COVID-19 epidemic? *Lancet.* 2020;395:931-4.
6. Zou L, Ruan F, Huang M, et al. SARS-CoV-2 viral load in upper respiratory specimens of infected patients. *N Engl J Med.* 2020;382:1177-9.
7. Guan WJ, Ni ZY, Hu Y, et al. Clinical Characteristics of coronavirus disease 2019 in China. *N Engl J Med.* 2020;382:1708-20.
8. Rodriguez-Morales AJ, Cardona-Ospina JA, Gutiérrez-Ocampo E, et al. Clinical, laboratory and imaging features of COVID-19: A systematic

- review and meta-analysis. *Travel Med Infect Dis.* 2020;34:101623.
9. Naming the coronavirus disease (COVID-19) and the virus that causes it; World Health Organization (WHO). (2020). Accessed: 4/2/2020: [https://www.who.int/emergencies/diseases/novel-coronavirus-2019/technical-guidance/naming-the-coronavirus-disease-\(covid-2019\)-and-the-virus-that-causes-it](https://www.who.int/emergencies/diseases/novel-coronavirus-2019/technical-guidance/naming-the-coronavirus-disease-(covid-2019)-and-the-virus-that-causes-it)
  10. The Novel Coronavirus Pneumonia Emergency Response Epidemiology Team. The epidemiological characteristics of an outbreak of 2019 novel coronavirus diseases (COVID-19) - China, 2020. *China CDC Week.* 2020;2:113-22.
  11. Wong HYF, Lam HYS, Fong AH, et al. Frequency and Distribution of Chest Radiographic Findings in Patients Positive for COVID-19. *Radiology.* 2020;296(2).
  12. Ai T, Yang Z, Hou H, et al. Correlation of Chest CT and RT-PCR Testing for Coronavirus Disease 2019 (COVID-19) in China: A Report of 1014 Cases. *Radiology.* 2020;296(2).
  13. Parry AH, Wani AH, Yaseen M, et al. Spectrum of chest computed tomographic (CT) findings in coronavirus disease-19 (COVID-19) patients in India. *Eur J Radiol.* 2020;129:109147.
  14. Zhao W, Zhong Z, Xie X, Yu Q, Liu J. Relation Between Chest CT Findings and Clinical Conditions of Coronavirus Disease (COVID-19) Pneumonia: A Multicenter Study. *AJR Am J Roentgenol.* 2020;214(5):1072-1077.
  15. Zhou S, Wang Y, Zhu T, Xia L. CT Features of Coronavirus Disease 2019 (COVID-19) Pneumonia in 62 Patients in Wuhan, China. *AJR Am J Roentgenol.* 2020;214(6):1287-1294.
  16. Li K, Wu J, Wu F, Guo D, Chen L, Fang Z, Li C. The Clinical and Chest CT Features Associated With Severe and Critical COVID-19 Pneumonia. *Invest Radiol.* 2020;55(6):327-331.
  17. Francone M, Iafrate F, Masci GM, et al. Chest CT score in COVID-19 patients: correlation with disease severity and short-term prognosis. *Eur Radiol.* 2020;30(12):6808-6817.
  18. Yoon SH, Lee KH, Kim JY, et al. Chest Radiographic and CT Findings of the 2019 Novel Coronavirus Disease (COVID-19): Analysis of Nine Patients Treated in Korea. *Korean J Radiol.* 2020;21(4):494-500.
  19. Cheng Z, Lu Y, Cao Q, et al. Clinical Features and Chest CT Manifestations of Coronavirus Disease 2019 (COVID-19) in a Single-Center Study in Shanghai, China. *AJR Am J Roentgenol.* 2020;215(1):121-126.
  20. Wang Y, Dong C, Hu Y, et al. Temporal Changes of CT Findings in 90 Patients with COVID-19 Pneumonia: A Longitudinal Study. *Radiology.* 2020;296(2)
  21. Ojha V, Mani A, Pandey NN, et al. CT in coronavirus disease 2019 (COVID-19): a systematic review of chest CT findings in 4410 adult patients. *Eur Radiol.* 2020;30(11):6129-6138.
  22. Zhao W, Zhong Z, Xie X, et al. Relation Between Chest CT Findings and Clinical Conditions of Coronavirus Disease (COVID-19) Pneumonia: A Multicenter Study.



- AJR Am J Roentgenol. 2020;214(5):1072-1077.
23. Pan Y, Guan H, Zhou S, et al. Initial CT findings and temporal changes in patients with the novel coronavirus pneumonia (2019-nCoV): a study of 63 patients in Wuhan, China. Eur Radiol. 2020;30(6):3306-3309.
24. Xu X, Yu C, Qu J, et al. Imaging and clinical features of patients with 2019 novel coronavirus SARS-CoV-2. Eur J Nucl Med Mol Imaging. 2020;47(5):1275-1280.
25. Francone M, Iafrate F, Masci GM, et al. Chest CT score in COVID-19 patients: correlation with disease severity and short-term prognosis. Eur Radiol. 2020;30(12):6808-6817.